

**TYPE OF ARTICLE:** Case Series white paper

**TITLE:** Novel, Integrated Rapid Exchange Pre-mounted, Single-Stent, Self-Detaching Delivery System for Biliary Stent Placement: Case Series of First-in-Human Experience.

**AUTHORS:** Dr Shay Matalon, MD

**AFFILIATIONS:** Head of Endoscopy Shamir Medical center

## **INTRODUCTION**

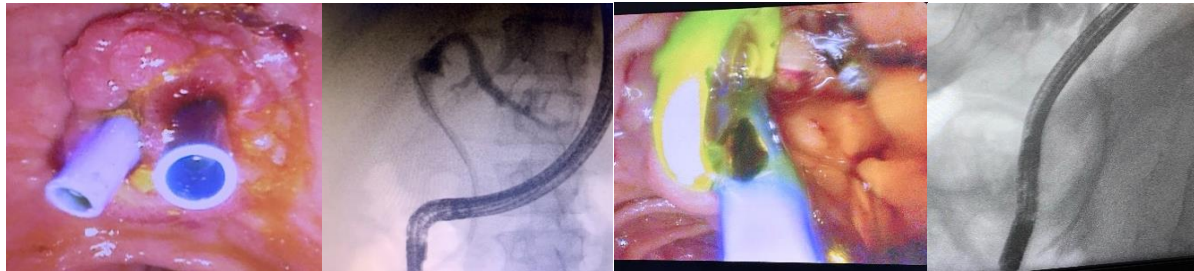
Current commercially available biliary stent delivery systems are limited by a loss of guidewire positioning after stent delivery, predominantly seen in cases with difficult ductal access requiring additional intervention following an index stent placement. A novel biliary stent delivery system, with integrated rapid exchange and self-detaching mechanism, has been developed to address these limitations. **(S-PATH system by EndoGI Medical)**. The primary objectives were to test this delivery system in human subjects for the first time to assess the success of the stent delivery, the localization of the stent within the bile ducts and post-delivery wire in-situ fixation. Secondary objectives included the ability of the device to reach its location within the bile duct, placement and location of the stent.

## **CASE SERIES**

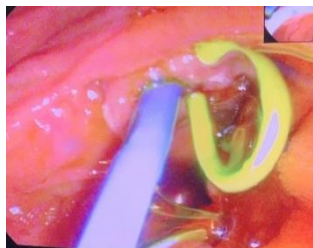
A series of patients undergoing biliary stent procedures for biliary obstruction due to Complicated biliary stone disease (n= 4), Obstructive jaundice due to malignant tumor (n=1), Unknown CBD drainage problem (n=1), Post Sphincterotomy bleeding (n=1) and Choledocholithiasis (n= 1) is described utilizing the novel stent delivery system.

The system was deployed with relative ease with all stents successfully placed into the required position without any wire dislocation. The delivery system was rated as easy-to-use, and appears to remain in-situ staying without migration following index stent delivery.

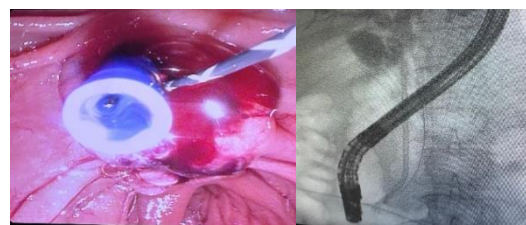
## Complicated biliary stone disease



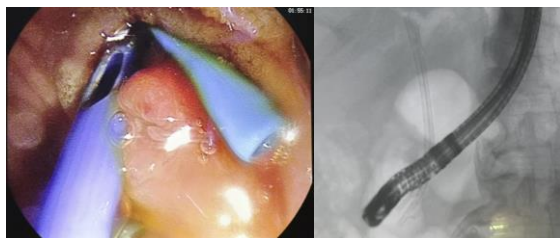
## Obstructive jaundice due to a malignant tumor



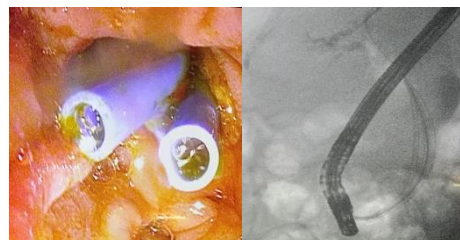
## Unknown CBD drainage problem



## Post Sphincterotomy bleeding



## Choledocholithiasis



## CONCLUSION

The novel single stent delivery system was successfully deployed 10FR by 90cm plastic in the case experience of one patient requiring stenting in the region of the common bile duct. The stents were successfully placed in-situ, with no procedural complications, enhancing procedural simplicity cutting procedural steps and time while ensuring secure and accurate ductal access and taking re-cannulation risks down.

**Keywords:** Biliary Stent, Pre-mounted, Novel Delivery System, In-situ Wire