

TYPE OF ARTICLE: Case Series white paper

TITLE: Novel, Integrated Rapid Exchange Pre-mounted, Single-Stent, Self-Detaching Delivery System for Biliary Stent Placement: Case Series of First-in-Human Experience.

AUTHORS: Dr Iyad Khamaysi

AFFILIATIONS:

Head of endoscopy Rambam Medical Center

INTRODUCTION

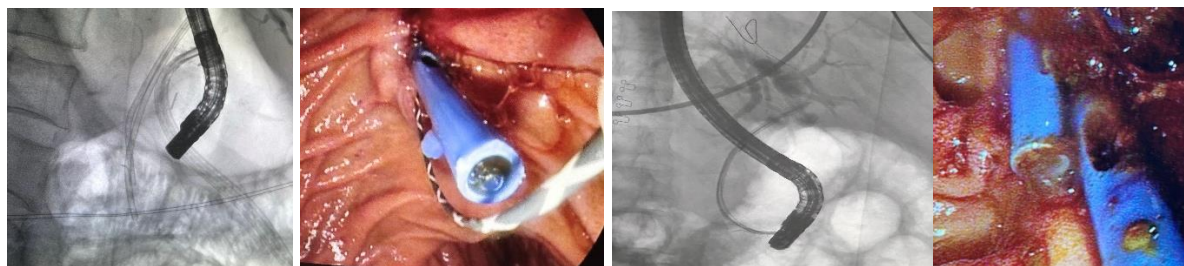
Current commercially available biliary stent delivery systems are limited by a loss of guidewire positioning after stent delivery, predominantly seen in cases with difficult ductal access requiring additional intervention following an index stent placement. A novel biliary stent delivery system, with integrated rapid exchange and self-detaching mechanism, has been developed to address these limitations. **(S-PATH system by EndoGI Medical)**. The primary objectives were to test this delivery system in human subjects for the first time to assess the success of the stent delivery, the localization of the stent within the bile ducts and post-delivery wire in-situ fixation. Secondary objectives included the ability of the device to reach its location within the bile duct, placement and location of the stent.

CASE SERIES

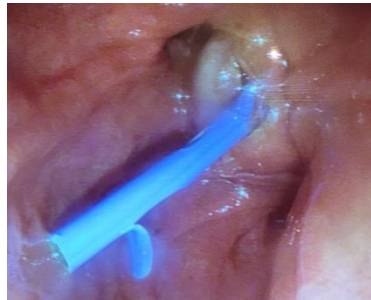A series of 10 patients undergoing biliary stent procedures for biliary obstruction due to Complicated biliary stone disease (n= 5), Gallbladder stone disease “Merezzi syndrome” (n=1), Post Cholecystectomy biliary stricture (n=1), Post Gallbladder resection Cystic duct Stone (n=1), Metal stent restenosis due to Malignant tumor “Massive ingrowth” (n=1) and Obstructive jaundice due to malignant tumour (n= 1) is described utilizing the novel stent delivery system.

The system was deployed with relative ease with all stents successfully placed into the required position without any wire dislocation. The delivery system was rated as easy-to-use, and appears to remain in-situ staying without migration following index stent delivery.

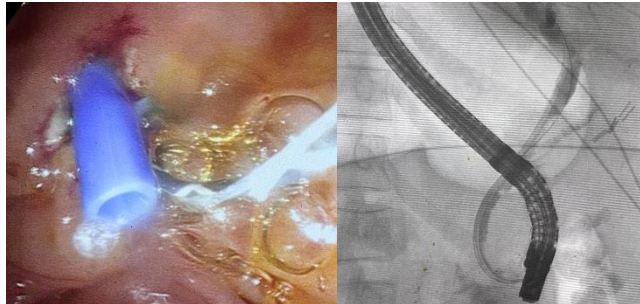
Complicated biliary stone disease



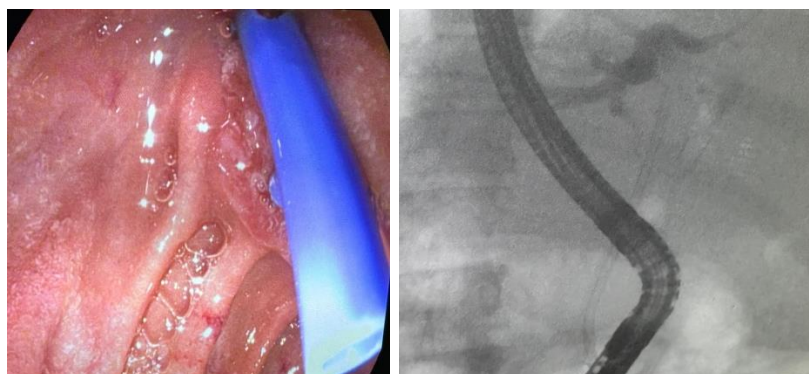
Gallbladder stone disease "Mirizzi syndrome"



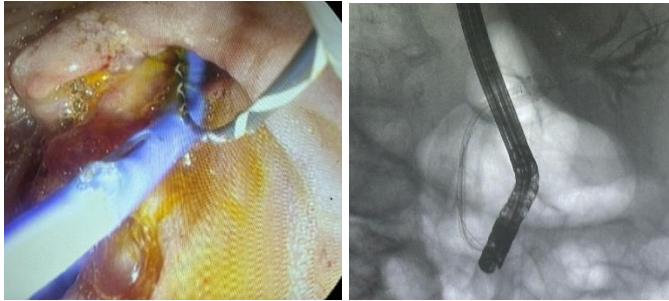
Post Cholecystectomy biliary stricture



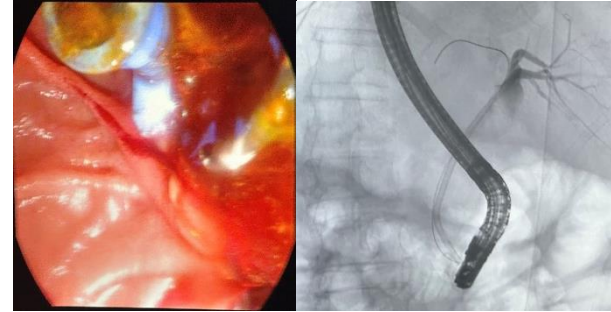
Post Gallbladder resection Cystic duct Stone



Metal stent restenosis due to Malignant tumor
“Massive ingrowth”



Obstructive jaundice due to
malignant tumour



CONCLUSION

The novel single stent delivery system was successfully deployed 10FR by 90cm plastic in the case experience of one patient requiring stenting in the region of the common bile duct. The stents were successfully placed in-situ, with no procedural complications, enhancing procedural simplicity cutting procedural steps and time while ensuring secure and accurate ductal access and taking re-cannulation risks down.

Keywords: Biliary Stent, Pre-mounted, Novel Delivery System, In-situ Wire